

FABRICATION OF CUSTOM OCULAR PROSTHESIS USING A GRAPH GRID.

Dr. Nidhi Dinesh Sinha, Dr. Aruna J Bhandari, Dr. S.A. Gangadhar

ABSTRACT:

Patients requiring treatment with custom ocular prosthesis are those who have lost ocular structures through orbital evisceration or orbital enucleation which was necessary as a surgical intervention for a congenital defect, pathology or an accident. The disfigurement associated with eye loss can cause significant physical and emotional disturbance. As iris placement is a technique sensitive procedure, visual assessment alone may not be accurate. The present article is an illustration of a case report of a lady chosen for a custom ocular prosthesis. The method described here uses a transparent grid template from which the iris is traced. An attempt is also made to mimick the shade and colour of the sclera in the wax pattern itself; using white paraffin wax. This gives an accurate registration of the position and alignment of iris disc assembly, giving a natural look.

Key words: *Custom ocular prosthesis, graph grid.*

INTRODUCTION

A congenital anomaly or pathology may necessitate an orbital evisceration or an orbital enucleation. The surgical procedure of evisceration is where the contents of the globe are removed, leaving the sclera intact. A more invasive procedure is enucleation where the entire eyeball is severed from the muscles and optic nerve. Exenteration^[1], the most radical, involves removal of the contents of the orbit.

The earliest known examples of restorations date to the fourth dynasty in Egypt; excavations of tombs have provided evidence of eye replacement by using precious stones, earthenware, copper, gold, enamelled bronze in the shrunken socket. Until World War II, the glass eye was the most popular prosthetic eye manufactured. The glass eye was however difficult to manufacture and hazardous when it exploded. One of the pioneers to use glass eye was Ambroise Pare (1510-1590). In 1944, Murphy and Nirroren fabricated physiologic ocular prosthesis in the United States Navy Dental Corps^[2]. Pare also used glass and porcelain for eyes, which was a great step forward. Later on methyl methacrylate prosthesis became popular since they offered superior strength and the shape and size could be modified. Recently flexible material such as silicone^[3]

became advantageous when the defect extends beyond the orbital area and encounters movable tissue beds. Lately in 2008, Satyabodh S. Guttal introduced a simple method of using a graph grid for accurate iris disc placement which has been used in the present illustration.

CASE REPORT

A fifty-five year old lady reported to the department of prosthodontics, Rural Dental College, Loni. She presented with evisceration performed four to five months prior on the right eye which was painful and blind. Keeping her paying capacity and other aesthetic requirement in mind she was elected for fabrication of a custom ocular prosthesis.

Evaluation of patient ocular defect

In a case of evisceration the extra ocular muscles are left intact and hence good mobility of the prosthesis is possible. So it becomes mandatory to do the defect evaluations. In accord to standard procedure; the palpebral fissure was observed both in open and closed position to rule out any abnormality. Evaluation of the muscular control of the palpebrae and the internal anatomy of the socket in resting position and full excursive movement was performed. Mobility of the

* Dept. of Prosthodontics, RDC, Loni.

posterior wall of the defect was assessed. Condition of conjunctiva, depth of fornices, and presence of cul de sac was noted.

Materials and Techniques –

Impression and wax pattern fabrication-The impression of the anophthalmic eye socket was sought by introducing an impression material into the eye socket using a disposable syringe and projecting it out between the lids. The impression material used here was irreversible hydrocolloid (ALGINATE). After the impression material was set, the impression was removed and invested in dental gypsum in order to obtain a positive cast of the eye socket. Subsequently the gypsum cast was coated with a separating medium and white paraffin wax was then shaped in an empirical approximation of the anterior curves of the investment form (Fig 1 and Fig 2).

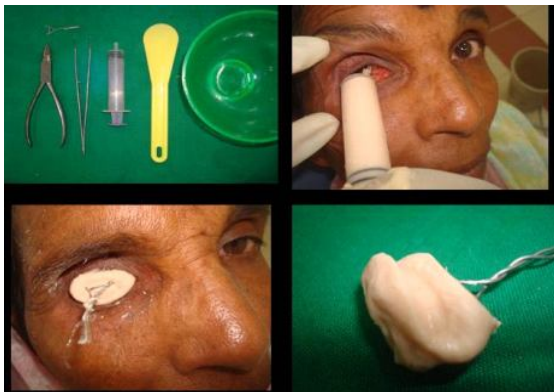

Figure 1: Impression of defect sought by irreversible hydrocolloid impression material.

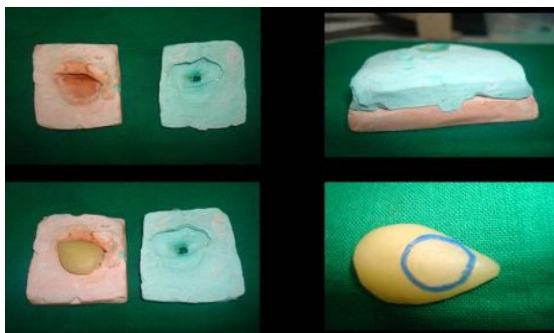


Fig: 2, Showing plaster cast and wax pattern

Trying the scleral wax pattern

Wax was added or trimmed from the basic scleral pattern until satisfactory contours of the eyelids were achieved in open and closed positions (Fig 3).

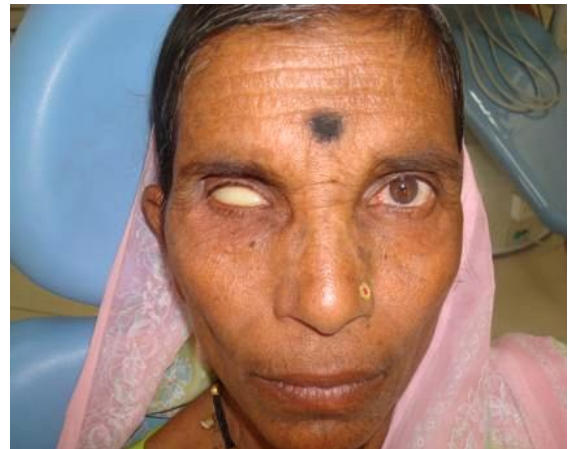

Fig 3: Try-in of wax pattern done

Technique of Iris Disc Placement

- 1 Transparent graph grid was used to attach iris disc.
- 2 Certain guidelines were marked on patients face.
- 3 The facial markings were transferred to grid by placing it on patients' face (Fig 4)

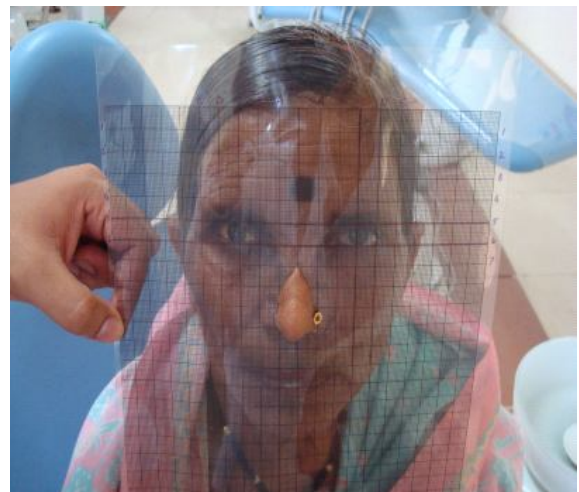

Fig4: Showing grid in place

The details of the technique are as follows;

Transparent graph grid

Markings were made on grid template on X-axis from A to H starting from midline and on left side from A' to H'. Similarly from 1 to 7 on Y-axis and 1' to 7' on left side. The distance between each marking was 1 cm on both X and Y axes.

Guidelines on patients face

A vertical midline was marked passing through the forehead crease, glabella, tip of the nose and chin. The distance from the right eye medial canthus to the midline and left eye medial canthus to the midline was measured. This distance standardized the midline marking and was used to reposition the grid template each time during the try-in visit.

Evaluation with grid placed

The patient was asked to gaze straight at an object kept 4 feet away. The operator then marked the vertical lines coinciding with the with the medial and distal extremities of the iris of the natural eye. Similarly the horizontal lines referring to the centre, inferior and superior limits of the iris were marked. The facial markings were transferred to the grid template by placing it on the patients face. These markings were transported to the side of the defect. These markings were transferred to the sculptured wax pattern and the iris button attached to it.

Investing, Dewaxing, Packing

The finished pattern was invested in a small two piece brass flask. A two part mold was constructed by the prototype ocular prosthesis by using dental gypsum in a two piece brass flask, the anterior portion of the mold was invested, a separating medium was applied and the posterior portion of the mold was then invested. The flask was then placed in a dewaxing bath for 20 min. The anterior and posterior portions of the flask were separated. The iris disc was shade matched with the adjacent eye and cut out from a stock eye. The color of the sclera was selected using tooth color acrylic shade guide.^[4]

Rayon thread fibrils^[5] were used to simulate vasculature, by monomer polymer syrup method. The selected shade of the sclera was matched with the heat cure resin which was then packed in the two piece flask. The flask was kept for curing for a period of two hours and thirty minutes to avoid any residual monomer.

Placement of ocular prosthesis

The patient was instructed on the aspects of insertion and easy removal of the prosthesis. (Fig 5)



Fig5: Final prosthesis polished and placed into the ocular defect.

Patient Follow up

The patient was asked to return on day 1, 2 and 7 for follow-ups after the prosthetic insertion. There after a 6 month follow-up was done for prosthesis evaluation and adjustment.

Discussion

The rehabilitation of the orbital defect is a complex task. A custom ocular prosthesis is a good option when reconstruction by plastic surgery or the use of osseointegrated implants is not possible or not desired. Systemic conditions and financial constraints may limit their use.

Advantages of a custom ocular prosthesis are:

- 1 Retains the shape of the socket.
- 2 Prevents collapse of the lids.
- 3 Provides proper muscular activity of the lids.
- 4 Prevents accumulation of fluid in the cavity.
- 5 Maintains palpebral opening similar to natural eye.
- 6 Has a gaze similar to natural eye
- 7 Mimics coloration and proportions of natural eye.
- 8 Conversational gaze can be achieved by maintaining precise interpupillary distance.

Conclusion:

The use of custom made ocular prosthesis has been a

boon to the average patient who cannot afford the expensive treatment options available. The procedure used here is cheaper, affordable and can be carried out in a small clinical set-up. This method has provided good results from patient esthetics, acceptance, and satisfaction points-of-view. Eye glasses that were used concealed the background effect and enhanced psychological comfort.

Acknowledgement

We are thankful to the Dept. of Ophthalmology, especially to Professor (Dr.) Somen Mishra, and Dr. (Mrs.) S.P. Nigvekar for their support and scientific inputs.

References

1. Satyabodh S.Guttal et al: A Simple Method of Positioning the Iris Disk on a Custom-Made Ocular Prosthesis. *Journal of Prosthodontics* 2008; 17:223-227.
2. Beumer J, Curtis TA. Maxillofacial Rehabilitation. *Prosthodontic and Surgical Considerations*; 431-49.
3. Manvi Supriya; Prosthodontic rehabilitation of a patient with an orbital defect using a simplified approach. *Journal of Indian Prosthodontic Society* 2008; 8, 2, 116-18.
4. Mc Arthur D.A.; Aids for positioning prosthetic eyes in orbital prosthesis. *J Prosthet Dent* 1977; 37:192-3
5. *Clinical Maxillofacial Prosthetics*; Thomas D. Taylor; p233-76.

